

Yellow Nail Syndrome: Diagnostic Value of Clinical Assessment and Occupational History

Klimis Sakellarios, Boulia Stavroula, Tsiplis Stamatios, Protogerou Aikaterini, Mouratidou Nefeli, Balis Evangelos
“Evangelismos” Athens General Hospital

ABSTRACT

Abstract

Introduction: Yellow Nail Syndrome (YNS) is a rare disorder characterized by the triad of yellow dystrophic nails, lymphedema, and respiratory manifestations such as pleural effusions or bronchiectasis. The etiology remains unclear while common associations include autoimmune diseases, malignancy, and titanium exposure.

Case Presentation: We present the case of a 62-year-old female, an ex-smoker and former hairdresser, with a history of asthma, allergic rhinitis, osteoarthritis, chronic bilateral lower limb lymphedema of unknown cause, and a left exudative pleural effusion four years earlier that resolved following video-assisted thoracoscopic (VATS). Biopsy showed nonspecific lymphocytic inflammation.

She presented to the emergency department with a three-week history of dry cough. A chest CT scan performed one month prior had revealed bilateral pleural effusions and cystic bronchiectasis localized to the lingula and right lower lobe. On examination, she had bilateral lower limb edema, yellow thickened nails of the upper and lower extremities, and distal phalangeal deformities. Vital signs and laboratory tests were unremarkable. Chest auscultation revealed diminished breath sounds at the lung bases.

Chest X-ray and ultrasound confirmed bilateral pleural effusions and small pericardial effusion. Ultrasound-guided pleurocentesis on both sides demonstrated lymphocytic exudative effusions. Bronchoscopy showed regional bronchial mucosal inflammation, and bronchoalveolar lavage microbiology was positive for *Pseudomonas Aeruginosa*.

Based on the characteristic triad of yellow dystrophic nails, chronic lymphedema, and pleuropulmonary involvement, a clinical diagnosis of **Yellow Nail Syndrome** was made. Further evaluation, including immunologic screening, mammography, and abdominal CT, excluded autoimmune and paraneoplastic etiologies. Given her occupational exposure to hair dyes—a potential source of titanium—nail and hair samples were obtained for qualitative titanium analysis.

Conclusion: This case illustrates a classic presentation of Yellow Nail Syndrome, emphasizing the importance of careful medical history and clinical examination in evaluating patients with unexplained pleural effusions. Occupational or medical titanium exposure, particularly represent a relevant environmental contributor.

CONTACT

Klimis Sakellarios
“Evangelismos” General Hospital of Athens
Email: arisklms13@gmail.com

INTRODUCTION

Yellow Nail Syndrome (YNS) is a rare disorder characterized by the triad of yellow dystrophic nails, lymphedema, and respiratory manifestations such as pleural effusions or bronchiectasis. The estimated prevalence is less than 1 in 1,000,000. The etiology remains unclear while common associations include autoimmune diseases, malignancy, and titanium exposure.

METHODS AND MATERIALS

We present the case of a 62-year-old female, an ex-smoker and former hairdresser, with a history of asthma, allergic rhinitis, osteoarthritis, chronic bilateral lower limb lymphedema of unknown cause, and a left exudative pleural effusion four years earlier that resolved following video-assisted thoracoscopic (VATS). Biopsy showed nonspecific lymphocytic inflammation. She presented to the emergency department with a three-week history of dry cough. A chest CT scan performed one month prior had revealed bilateral pleural effusions and cystic bronchiectasis localized to the lingula and right lower lobe (figure 1). On examination, she had bilateral lower limb edema (figure 2), yellow, thickened and slow-growing nails of the upper and lower extremities (figure 3). Vital signs and laboratory tests were unremarkable. Chest auscultation revealed diminished breath sounds at the lung bases.

RESULTS

Chest X-ray and ultrasound confirmed bilateral pleural effusions and small pericardial effusion. Ultrasound-guided pleurocentesis on both sides demonstrated lymphocytic exudative effusions. Bronchoscopy showed regional bronchial mucosal inflammation, while bronchoalveolar lavage microbiology was positive for *Pseudomonas aeruginosa* and she was treated with an oral antibiotic course.

Based on the characteristic triad of yellow dystrophic nails, chronic lymphedema, and pleuropulmonary involvement, a clinical diagnosis of **Yellow Nail Syndrome** was made.

Further evaluation, including autoimmune disease screening, mammography, and abdominal CT, excluded autoimmune and paraneoplastic etiologies. Given her prolonged occupational exposure to hair dyes—a potential source of titanium—nail and hair samples were obtained for qualitative and quantitative titanium analysis.

CONCLUSIONS

This case illustrates a classic presentation of Yellow Nail Syndrome, emphasizing the importance of careful medical history and clinical examination in evaluating patients with unexplained pleural effusions. Occupational or medical titanium exposure, particularly represent a relevant environmental contributor.

REFERENCES

- Cheslock M, Harrington DW. Yellow Nail Syndrome. In: StatPearls [Internet]. Treasure Island (FL): StatPearls Publishing; 2025 Jan-. Updated September 19, 2022. Accessed December 11, 2025. <https://www.ncbi.nlm.nih.gov/books/NBK557760/> NCB1
- Decker A, Daly D, Scher RK. Role of titanium in the development of yellow nail syndrome. *Skin Appendage Disord.* 2015;1(1):28-30. doi:10.1159/000375171. Accessed December 11, 2025. <https://pmc.ncbi.nlm.nih.gov/articles/PMC4857837/>

Figure 1. Chest CT of the patient showing left pleural effusion and cystic bronchiectasis.

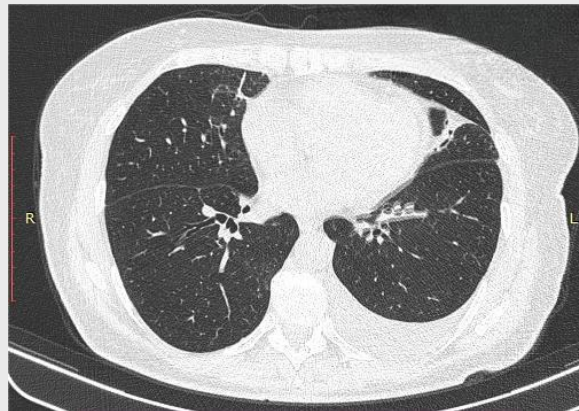


Figure 2. Photo of the patient demonstrating bilateral lower limb lymphedema.

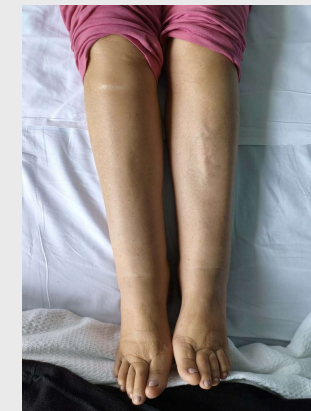

Figure 3. Photo of the patient demonstrating the characteristic nail changes associated with YNS

