



Safety, Performance And Clinical Benefits Of Combined Anterolateral Ligament And Anterior Cruciate Ligament Reconstruction. A Retrospective Consecutive Series Study

I. Bampis, A. Stamatopoulos, K. Bekas, , A.Papadimitriou, N. Zervakis, A. Boutsiadis

Background

Anterior cruciate ligament (ACL) reconstruction remains the treatment of choice in almost all active patients with an ACL injury. **Combined** ACL and anterolateral ligament (ALL) reconstruction are associated with:

- ▶ significantly lower risk of ACL graft rupture
- ▶ significantly lower risk of reoperation for secondary meniscectomy following medial meniscal repair at the time of ACL reconstruction
- ▶ significantly increase likelihood of return to the preinjury level of sport following primary
- ▶ excellent clinical outcomes

Objectives

The aim of this single-center, retrospective, consecutive series clinical follow-up study is to evaluate the safety, performance and clinical benefits of the combined ALL and ACL reconstruction using the ExpressBraid Graft Manipulation (ExpressBraid) for ALL graft preparation in combination with the ToggleLoc ZipLoop and/or ToggleLoc XL with ZipLoop Inline for graft fixation and the effect that has in meniscal repair.

Method/ Technique

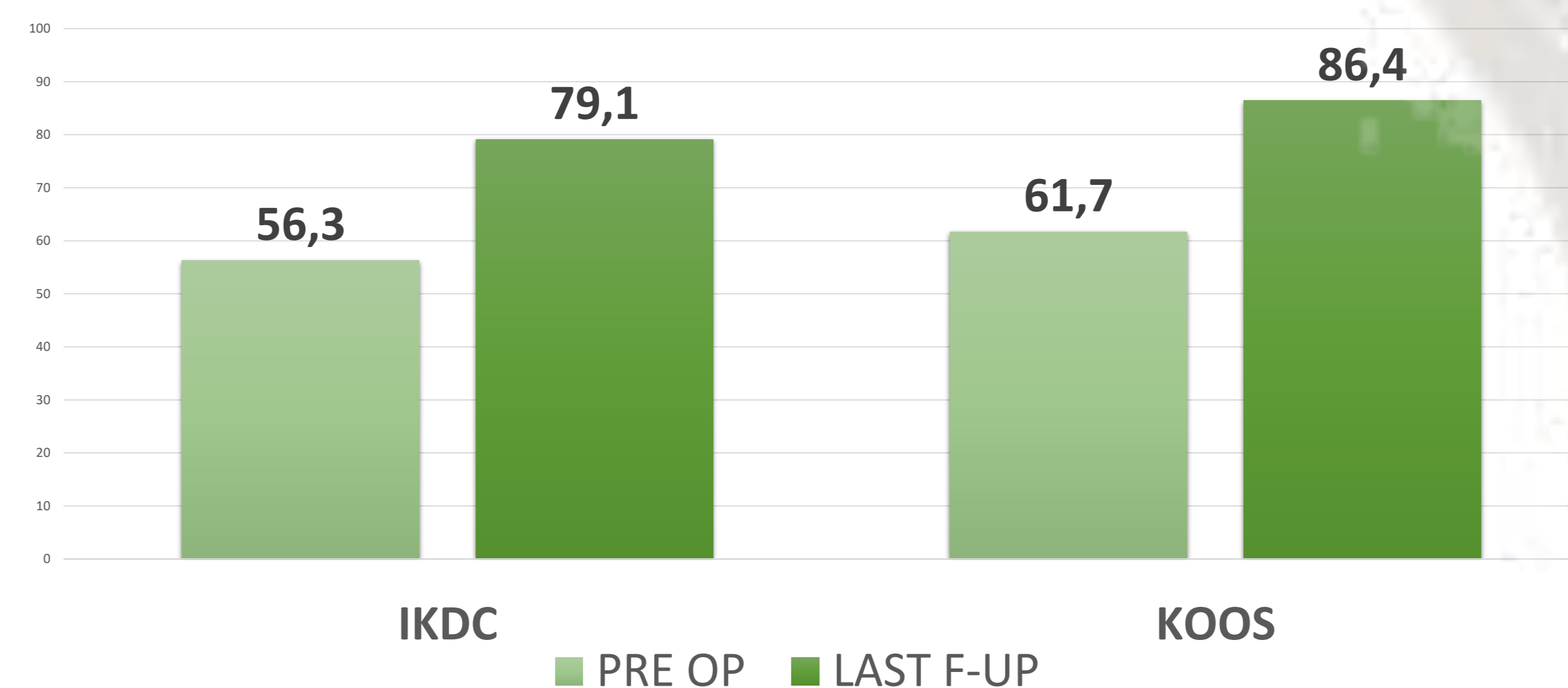
- ❖ 54 patients underwent combined ALL and ACL reconstruction between 17 January 2018 and 18 June 2021.
- ❖ Mean postoperative follow-up of 1.2 years (1-1.8 months)
- ❖ Meniscus:
 - Medial meniscus repair 17/54
 - Lateral meniscus repair 3/54
 - Both meniscus repair 15/54

- ❖ Soft tissue approximation and ligation and soft tissue to bone fixation were assessed by analyzing the incidence and frequency of revision surgeries.
- ❖ Safety was assessed by recording and analyzing the incidence and frequency of complications and adverse events.
- ❖ The relation of the events to implant, instrumentation and procedure was also specified.
- ❖ Finally, clinical benefits were evaluated by the Knee Injury and Osteoarthritis Outcome Score (KOOS) and International Knee Documentation Committee (IKDC questionnaire).

Results

- ✓ 2 patients required reoperation.
 - 1 patient underwent revision surgery due to ACL re-rupture following a work accident (raw revision rate of 1.9%).
 - 1 patient a tear of the medial meniscus two years postoperatively.
 - None of the repaired meniscus needed to be revised.

- ✓ Subjected patient's outcomes:



- ✓ Mean knee **laxity** pre- operatively was 10.2 mm (± 2.1) and improved to 2.4 mm (± 1.0).
- ✓ Anterior-posterior (Lachman test) and rotatory knee **instability** (pivot swift test) has improved in all cases, and most of them returned to normal stability (N=48) or were graded as mild instability (N=6).
- ✓ **Pain** in the final follow up was none for 44 patients , very mild and mild for 8 and moderate in 2.

Conclusions

To conclude, our preliminary results confirm that combined ALL and ACL reconstruction using the ExpressBraid Graft Manipulation (ExpressBraid) for ALL preparation in combination with the ToggleLoc ZipLoop and/or ToggleLoc XL with ZipLoop Inline for graft fixation offers anterior-posterior and rotatory knee stability, and protects both medial and lateral meniscus repairs without adding pain in final outcomes.

References

- Boutsiadis A., Brossard P., Panisset JC., Graveleau N., Barth J. Minimally Invasive Combined Anterior and Anterolateral Stabilization of the Knee Using Hamstring Tendons and Adjustable-Loop Suspensory Fixation Device: Surgical Technique. *Arthrosc Tech*. 2017 Apr; 6(2): e419–e425.
- Saithna A.,Daggett M.,Helito P,Monaco E, Franck F, Vieira T, Pioger C, Kim JG, Sonnery-Cottet B, Clinical Results of Combined ACL and Anterolateral Ligament Reconstruction: A Narrative Review from the SANTI Study Group. *J Knee Surg* 2021 Jul;34(9):962-970
- Sonnery-Cottet B, Saithna A, Blakeney W, Ouanezar H, Borade A, Daggett M, Thauan M, Fayard J-M, Delaloye J-R, Anterolateral Ligament Reconstruction Protects the Repaired Medial Meniscus: A Comparative Study of 383 Anterior Cruciate Ligament Reconstructions From the SANTI Study Group With a Minimum Follow-up of 2 Years. *Am J Sports Med* 2018 Jul;46(8):1819-1826