
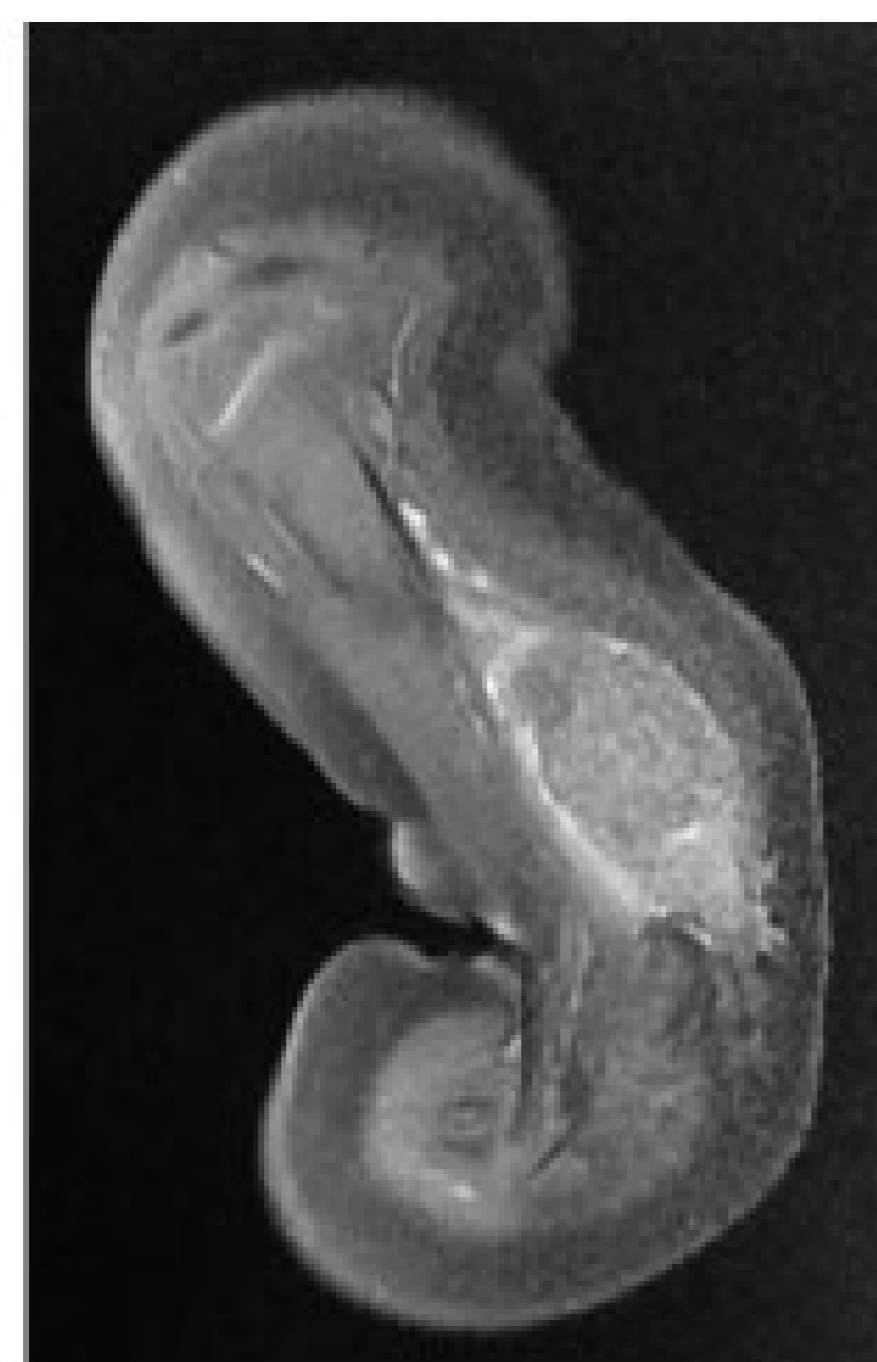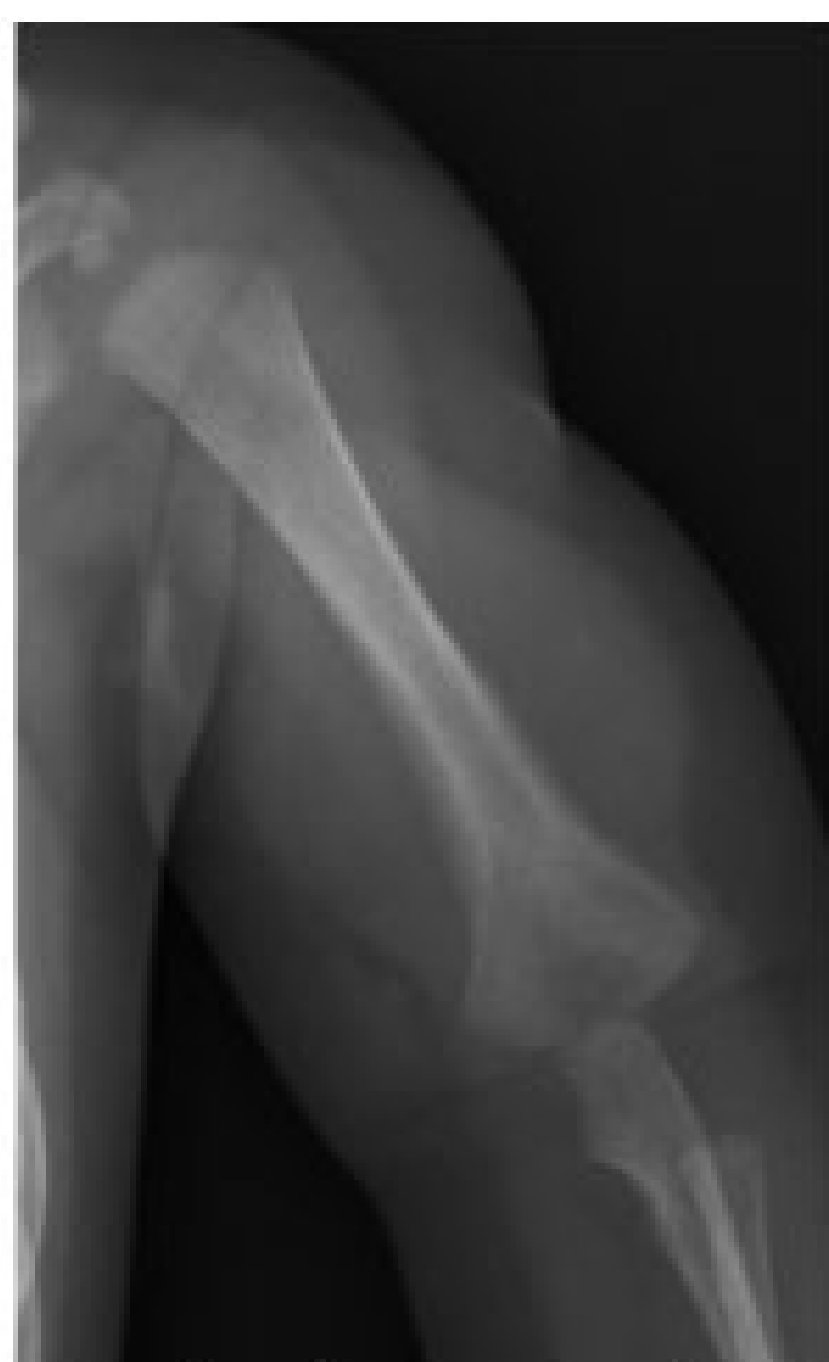


Ewing Sarcoma in 8 month old girl

Author: A. Szafranski M.D. Ph.D.




Children's Memorial Health Institute in Warsaw, Poland
Department of Oncology

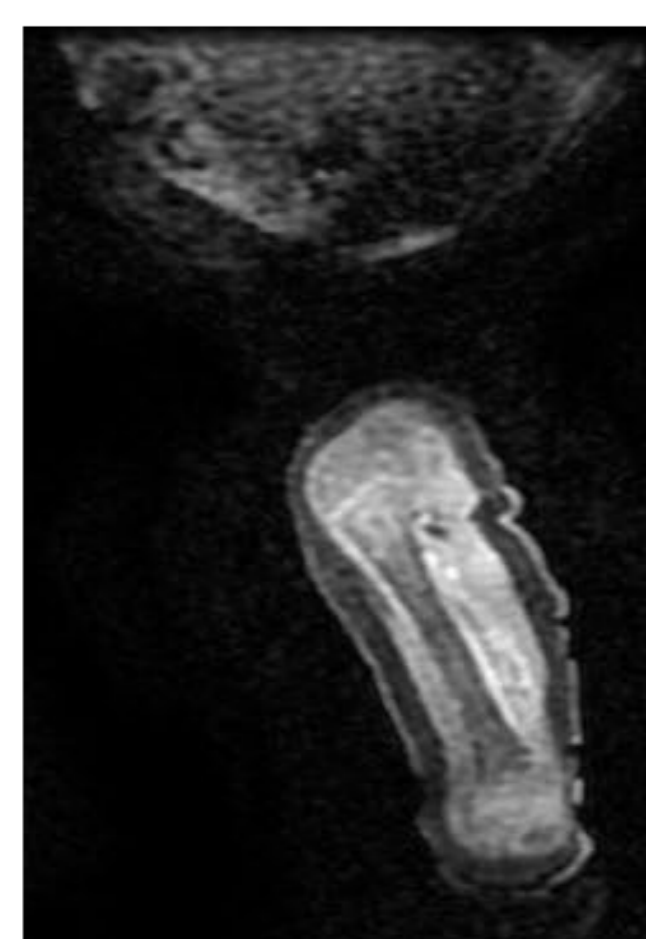

6-month-old girl with a large left arm tumor detected after birth. After the biopsy, Ewing's sarcoma was diagnosed. The performed imaging examinations showed a large tumor comprising 2/3 of the left left humerus with a large tumor in soft and exalted tissues. In addition, a metastatic lesion was visible in the proximal left humerus. There were no metastatic lesions in the remaining bones and in the lungs.

1/5

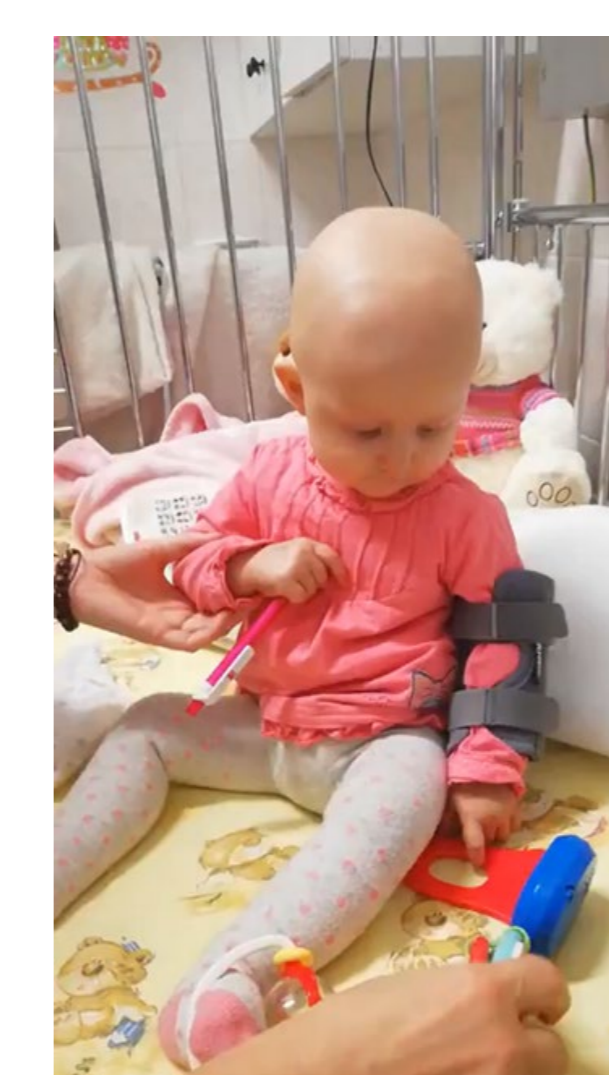
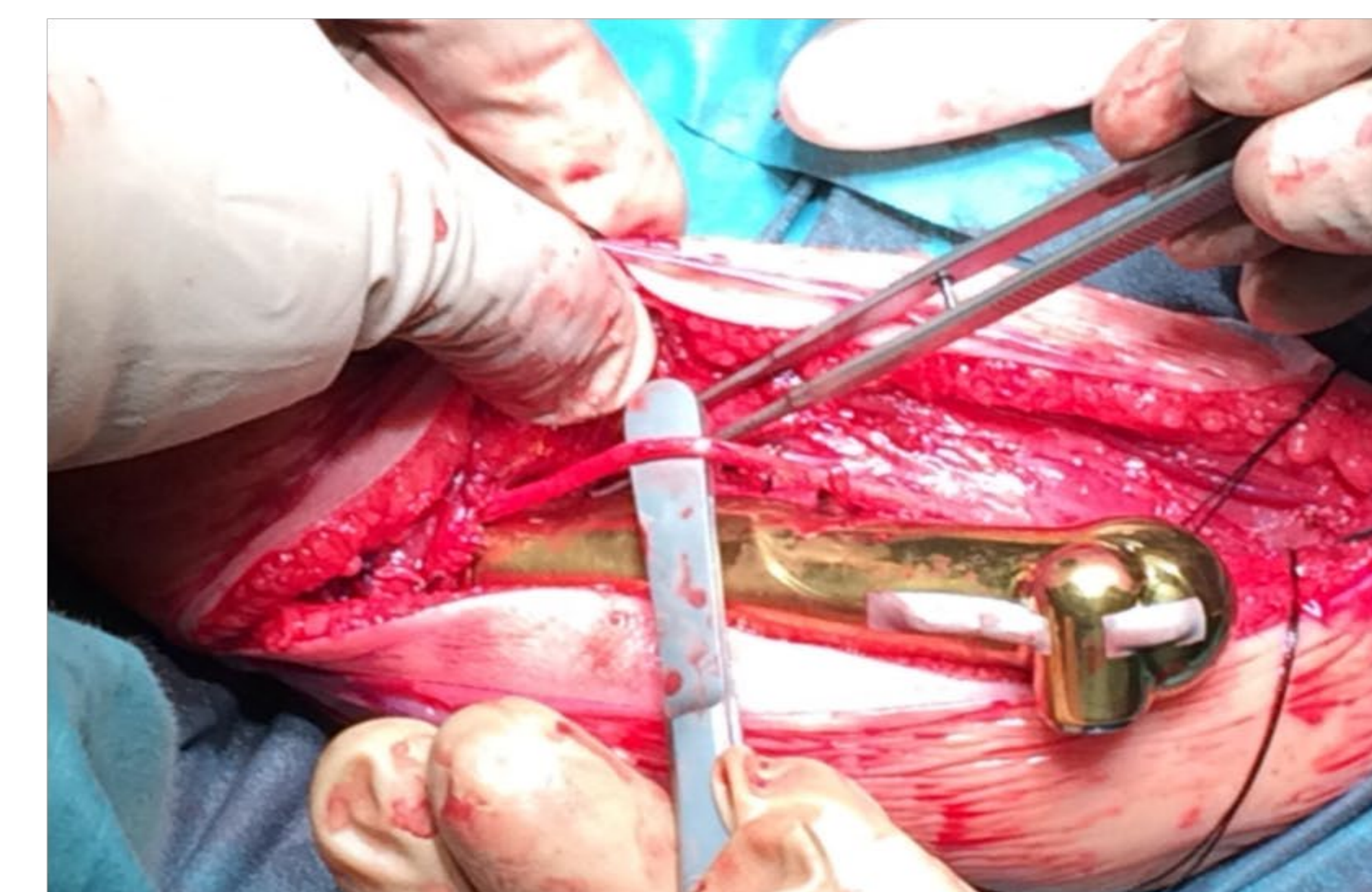
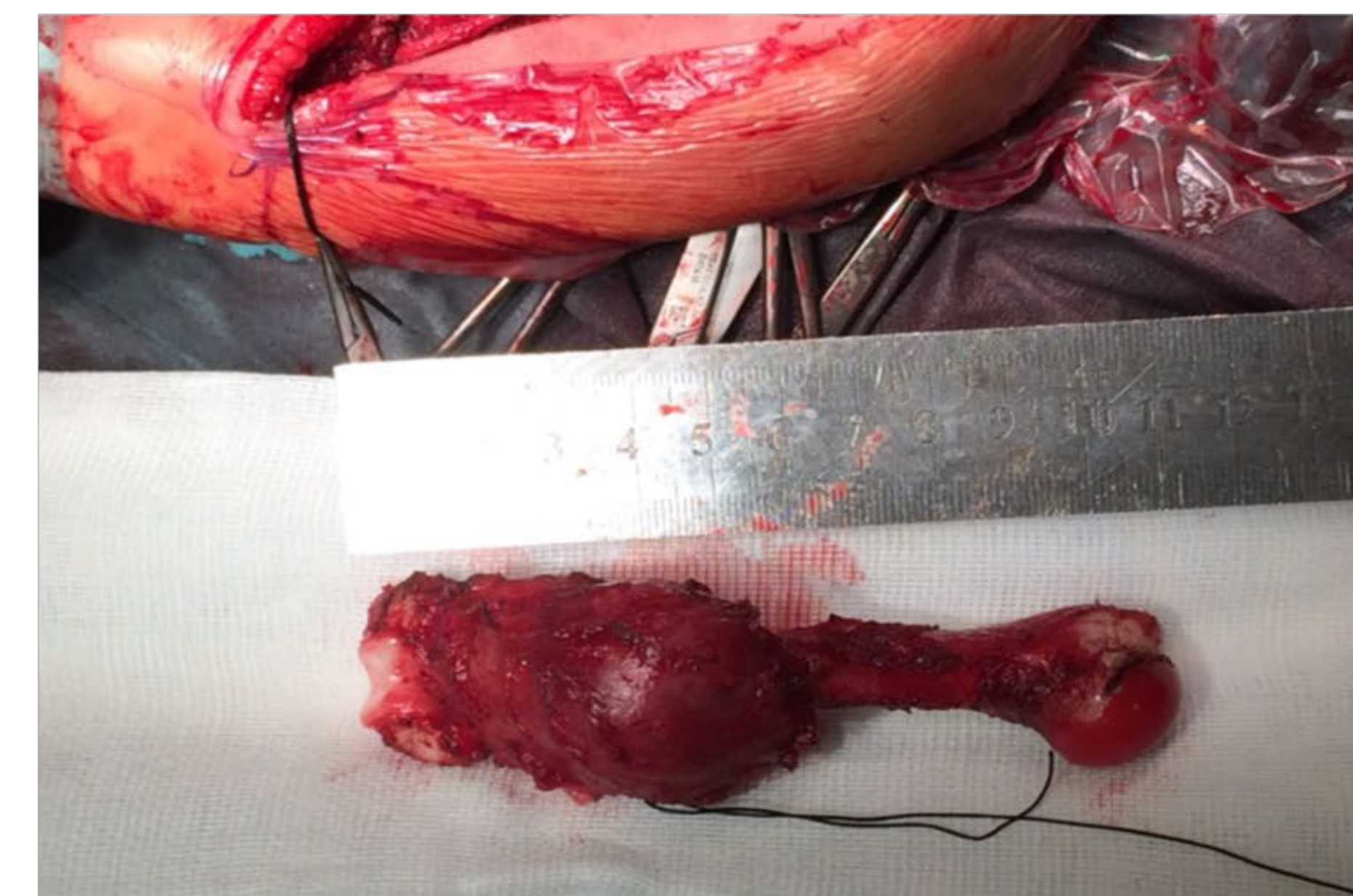


The tumor volume decreased 3 times. This allowed to plan the removal of the tumor along with the entire humerus and soft tissue tumor. In order to re-construct the resulting cavity, the humeral endoprosthesis was made using the 3 D printing technique.



The procedure was performed on 5/12/2017. No complications were observed after the procedure. Currently, the patient continues adjuvant chemotherapy. The treatment was radical surgical-ly. Intensive rehabilitation was applied. A full range of move-ments was achieved both in the shoulder and elbow joints. There were no movement and sensory deficits in the left arm. We consider the treatment effect as very good.

Conclusion: the 3D technique allows the preparation of even whole bone implants for a particular patient. This allows you to restore full operative efficiency of the operated limb. It was the first such treatment in the world.



2/5